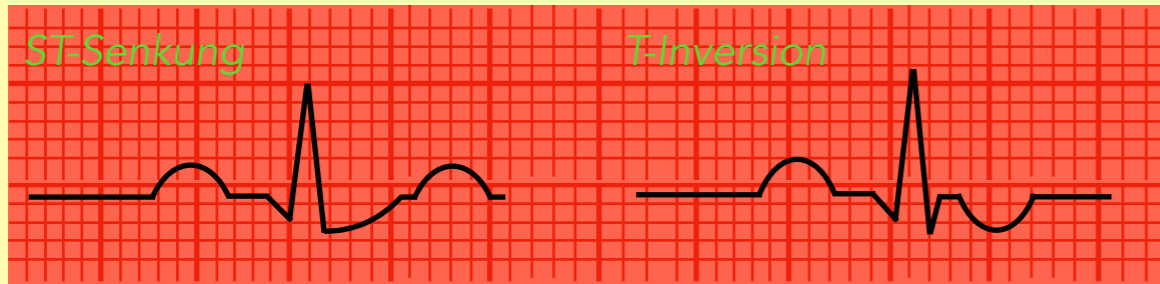


Instabile Angina pectoris

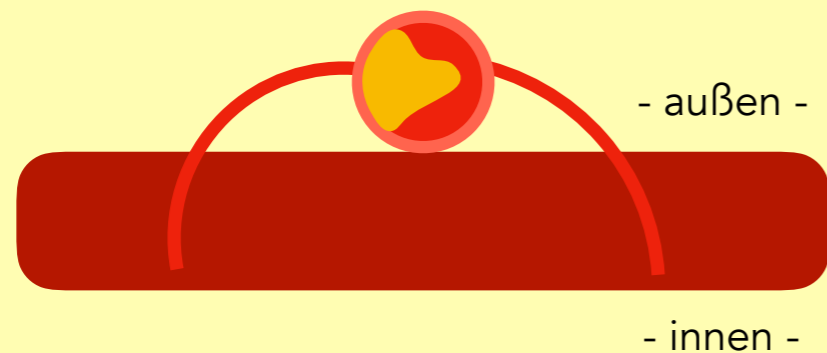
EKG: normal oder unspezifisch



Koronargefäß mit Plaque



keine Myokardnekrose



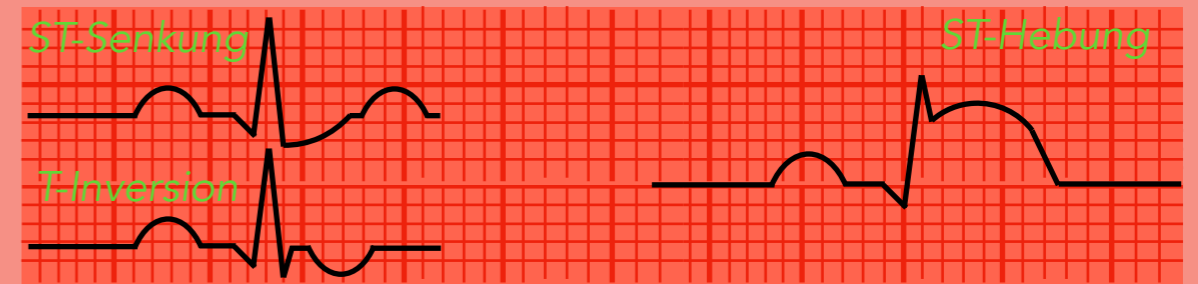
Troponin negativ

Akuter Myokardinfarkt


NSTEMI

EKG

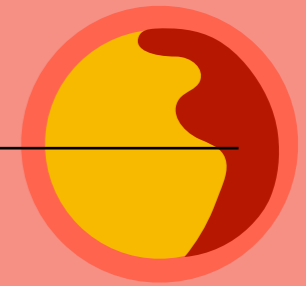
STEMI



Koronargefäß mit Plaqueruptur



hochgradig stenosierend



komplett stenosierend


Myokardnekrose

subendokardial

transmural



irreversible
Innenschichtischämie



irreversible transmurale
Ischämie

Troponin positiv