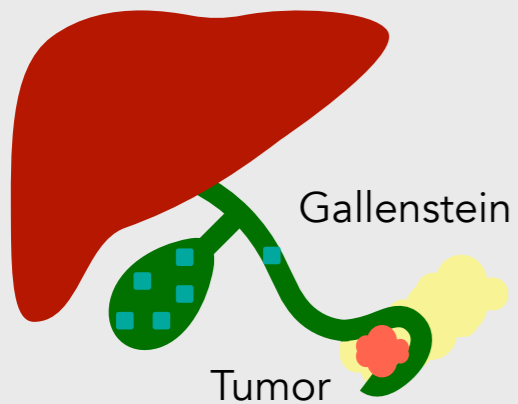


Posthepatischer Ikterus

Ursache

Cholestase



Labor

direktes
Bilirubin



gamma-GT
AP



Urin

braun

Bilirubin +

Stuhl

hell